

Toxicity of *Anagallis arvensis* Plant

S. I. AL-Sultan¹, Y. A. Hussein² and A. Hegazy³

¹Department of Public Health and Animal Husbandry, College of Veterinary Medicine and Animal Resources, King Faisal University, P. O. Box 11647, Al-Ahsa 31982, Saudi Arabia

²Department of Clinical Studies, College of Veterinary Medicine and Animal Resources, King Faisal University, P. O. Box 11647, Al-Ahsa 31982, Saudi Arabia

³Department of Pathology, College of Veterinary Medicine and Animal Resources, King Faisal University, P. O. Box 11647, Al-Ahsa 31982, Saudi Arabia
E-mail: alsultan87@hotmail.com

Abstract: Sixty adult rats of both sexes were used for determination of LD₅₀ of *Anagallis arvensis*. Other eighteen rats were used for repeated successive dose for determination of blood picture, kidney function and histopathological changes associated with *A. arvensis* toxicosis (1/5 and 1/10 LD₅₀) IP for 15 days. The LD₅₀ was 10.718 mg/kg.b.wt. of alcoholic extract of *A. arvensis*. The clinical signs included anorexia, restlessness, diarrhea, thirst, difficult breathing, tremors and ended by coma and death. Hematologically, there were a significant reduction in PCV%, Hb concentration and RBCs count of the intoxicated rats. Concerning kidney function tests, there were a significant increase in urea and creatinine level of the intoxicated rats. Pathologically, the lesions were primarily confined to the urinary system.

Key word: *Anagallis arvensis*, rat, alcoholic extracts, Saudi Arabia

Introduction

Poisonous plants are widely distributed all over the world. These plants are considered those which, when eaten, can give rise to a departure from the normal health of man and domestic animals. The toxicity of plants has been known since the beginning of recorded history. Records of harmful effects by many of these plants are based solely on poisoning of livestock rather than on actual cases of human ingestion.

Many weed infest Saudian field: one of these is *Anagallis arvensis*, which is decidedly poisonous to small animals and sheep (Miller, 1935; Wahby, 1942), and that it may adversely affect large animals specially horses fed in great quantities of green fodder heavily infested with this weed (Georgia, 1923; Lander, 1944). Also, *Anagallis arvensis* has been caused poisoning in sheep in Australia on various occasions (Hurst, 1942) and its toxicity has been confirmed by experiment (Pullar, 1939). However, the plant is reported to produce gastrointestinal symptom in the dog and horse, to be toxic to poultry and rabbit and (the seed) to birds (Watt and Breyer-Brandwijk, 1962). More recently in South Africa (Schneider, 1978) poisoning of sheep, all of which died, was attributed to *Anagallis arvensis* after other sheep had been fed experimentally with the plant and developed the same clinical signs. These included difficult breathing, depression, stiffness of gait, leg weakness, recumbency and in the terminal stages, coma and rapid drop in body temperature. Typical post-mortem lesions are hemorrhage of the kidneys, heart and intestines and congestion of the lungs and liver. Therefore, (Kotb, 1985) reported that the active principle

of *Anagallis arvensis* were acired volatile oil, enzymes, saponins, tannins, bitter principle and a compound known as primin. Roots contain cyclamen, a crystallizable glucosidal saponin. The oil produce headache lasts for 24 hrs. The plant was toxic to dog, rabbits and sheep. Signs of toxicity were general depression, thirst and diarrhea. Also, Chevallier (1996), recorded that *Anagallis arvensis* contains saponins (including anagallin), tannins and cytotoxic. However, Riet-Correa *et al.* (1998) reported that four cases of *Anagallis arvensis* poisoning were diagnosed in the Department of Psysandu, Uruguay during December, 1994 and January, 1995, in barely and stubble fields. Cattle of different ages were affected. Morbidity was 7-30% and case fatality was 50-86%. In two cases the animals had been introduced in the stubble field 7-15 days before the observation of clinical case. In to others the animals were in the fields 30-45 days before developing clinical signs. Eight of 289 ewes died after grazing in the same field that had affected cattle. Another case was observed in sheep and cattle with calves with no clinical signs in the calves. Clinical signs included anorexia, restlessness, weight loss, haemorrhagic diarrhea, muscular tremors and convulsion. Serum urea, creatinine and magnesium were increased. Clinical manifestation periods was 2-15 days. Gross lesions were characterized by petechial haemorrhage and edema of the mesentery, presence of clear yellowish fluid in the cavities, erosive and ulcerative lesions in the esophagus, haemorrhagic abomasitis and enteritis, perirenal edema and yellowish discoloration of the kidneys. The main histologic

lesion was a severe tubular nephrosis. Sadekar *et al.*, 1996 have been observed dullness, anorexia and constipation of feeding *Anagallis arvensis* also pathological changes in kidneys and livers.

Materials and Methods

Plant materials: *Anagallis arvensis* were freshly collected from various farms in Al-ahsa. Approximately 1 kg of dried plant materials was ground and extracted with 80% ethanol by shaking and percolation for 24 hours at a room temperature. The extract were pooled and centrifuged at 1000 rpm for 10 minutes. The solvent of supernatant liquid was removed completely by evaporation under vacuum. Prior to drug administration the residue was dissolved or suspended in distilled water. White albino rats of both sexes were used in this investigation. These animals were clinical healthy and weighing 150-200 g. Rats were housed in hygienic fiber glass cages. They were obtained from college of Veterinary Medicine and Animals Resources, King Faisal University. Animals were fed on commercial pellets, obtained from Grain Silos and Flour Mills Organization, Riyadh. These rats were used for assay of different toxic dose levels in experimental toxicity testes. Through the study all animals were observed once daily for clinical and signs of toxicity.

The determination of the LD₅₀: According to the method of Weill (1952) for determination of the dose of LD₅₀, exploratory trials were performed in five groups each of two rats, alcoholic extract was administrated intraperitoneally (IP) at doses of 5,10, 20 and 30 mg/kg b.wt.

Correspondingly in the five groups to find the smallest toxic dose to start with. The dose 5mg/kg.b.wt. which was the first dose to cause signs of toxicity multiplied by constant factor (2) for each succeeding groups of rats. Five groups of rats were used (10 of each), four groups were 5, 10, 20 and 40mg/kg.b.wt. alcoholic extract respectively. Groups five was used kept as a control. Mortality rats was record after 24 hr .

Studies of repeated administration of *Anagallis arvensis* extract in the rats, eighteen adult rats of both sexes were divided into 3 equal groups (6 rats each). The 1st and 2nd groups were daily IP injected with (2.359 and 1.072) about 1/5 and 1/10 LD₅₀ aqueous solution of *Anagallis arvensis* alcoholic extract respectively. The 3rd group was injected by sterile saline solution and kept as a control. All rats were kept under observation for 15 days. At the end of experiment all rats were sacrificed.

Hemoglobin concentration was determined according to Sahli's methods (Schalm,1975) red and white cell count were done using the double improved Neubauer chamber (Wintrobe,1967) and packed cell volume (PCV) was calculated by microhaematocrite tube as described by (Schalm,1975).

Serum samples, following sacrifice were used to determine urea according to Fawcett and Scott (1960) and serum creatinine according to Seeling and Wust (1969) methods.

The post mortem examination was applied for all the sacrificed rats of the three groups and specimens were collected from various organs. The latter specimens were fixed 10% neutral buffer formaline and then routinely processed in paraffin technique, for the microscopic examination after staining by haematoxylin and eosin stain, Culling (1974).

Results

LD₅₀ Determination:

Table 1 : The percent (%) of animals died after injection of *Anagallis arvensis* alcoholic extract IP

No.of animals/ group	Dose of <i>A. arvensis</i> extract mg/kg.b.wt.	No.of animals died	% of animals died
10	5	0	0
10	10	4	40
10	20	10	100
10	40	10	100
10	---	---	---

Log m = Da+d (f+1), Where:

Da = The log of the lowest of the four dosage level used.
d = The logarithm of the constant ratio between dosage levels. f = A constant factor from Weil tables

$$\begin{aligned} \text{Log m} &= \log 5 + \log 2 (0.1+1) \\ &= 0.69897+0.30103(1.1) \\ &= 0.69897+ 0.331133 \\ &= 1.03013 \end{aligned}$$

$$\text{Antilog} = 10.718$$

$$\text{LD}_{50} = 10.718 \text{ mg/kg.b.wt.}$$

Anagallis arvensis produce gastrointestinal symptoms. Rats suffered from anorexia, restlessness, diarrhea, thirst (the animal goes toward drinking water), difficult breathing, tremors and ended by coma and death of some individuals. There was haematological changes RBCs, Hb and PCV were significantly decreased P< 0.05 as compared with the normal in both dose levels. WBCs count was showed non-significant change, Table 2. Biochemical changes were urea and creatinine level was increased significantly in both dose levels, Table 3.

P. M. Lesions: There were hemorrhage of the kidneys, heart and intestine and congestion of the lung and liver. Prostate gland was enlarged as compared with normal, Fig. 2.

Histopathological changes

High Dose

Log: Areas of chronic interstitial pneumonitis and

Table 2: Duncan multiple range test for hematological studies of rats administered *Anagallis arvensis* alcoholic extracts

Treatment	PVC%	Hb gm/100 ml	RBCs 10mm	WBCs 10 mm
	Mean ± S.E.	Mean ± S.E.	Mean ± S.E.	Mean ± S.E.
Control	41.25±0.50	14.4±0.18	8.20 ±0.14	8.58 ±0.10
A	34.75±0.96	10.98±0.17	6.00±0.08	8.15±0.31
B	37.83±2.04	12.20±0.20	7.33±0.19	8.02±0.16

All means within the same column and having the same superscript are not significantly different from each other. Where Control = mean of control group, A = mean of group 1/5 of LD₅₀, B = mean of group 1/10 of LD₅₀, P< 0.05

Table 3: Duncean multiple range test for some of kidney function tests of administrated *Anagallis arvensis* alcoholic extracts

Treatment	Urea mg/dl	Creatinine mg/dl
	Mean ± S.E.	Mean ± S.E.
Control	31.80±2.59	0.50±0.04
A	50.75±5.74	0.74±0.12
B	41.67±2.16	0.62±0.03
C	50.75±5.74	0.74±0.12

All means within the same column and having the same superscript are not significantly different from each other. Where A = mean of control group. B = mean of group 1/10 of LD₅₀ C = mean of group 1/5 of LD₅₀

alveolar emphysema were seen. Bronchitis and bronchiolitis associated with peri-bronchial lymphocytic hyperplasia were also detected. The epithelium cells lining, the bronchial mucosa showed marked goblet cell hyperplasia, Fig. 3, 4 and 5.

Liver : In one case marked venous congestion have been observed. Hepatocyte appeared swollen and fine vaculated. Occasional foci and single cell necrosis associated with inflammatory cell infiltration and kupper cell hyperplasia were seen in four animals, Fig. 6.

Kidney : Thickening of the basement membrane of the glomeruli and degeneration of the renal tubuler epithelium characterized by dilatation of renal tubules and vacuolization of the aggregation were seen. Occasional gromuli appeared atrophy with dilatation of Bowman's capsule and accumulation of serous fluid.

Prostate Gland: In one case acute prostatitis characterized by massive accumulation of neutrophils in the lumen of the prostatic acini as well as the interstitial tissue in addition to congestion and edema of interstitial tissue in addition to congestion and edema of interstitial tissue have been observed, Fig. 7.

Heart : Mild peri-vascular edema

Testis: Congestion with small areas of intertubular hemorrhage were seen, Fig. 8.



Fig. 1: Varieties of *Anagallis arvensis* plant

Brain: Congestion of meningeal vessels was detected.

Low Dose

Kidney: Some of the cortical tubules were lined with vacuolated epithelial cells with hyaline casts in their lumen. Few basophilic cortical tubules were seen, Fig. 9 and 10.

Spleen : No abnormality detected.

Lung: Areas of chronic interstitial pneumonitis and endarteritis obliterans have been seen in the four cases, Fig. 11.

Liver: Hyperplasia of kuffer cell and small foci of parenchymal necrosis infiltrated by mononuclear cells were seen Fig. 12 and 13.

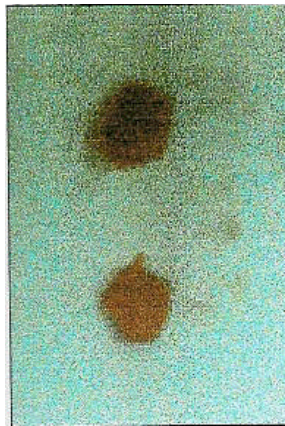



Fig. 2: Enlargement of prostate gland

Heart: Mild myodegeneration.

Testis: No abnormalities detected.

Brain: Congestion of the meningeal vessels.

Prostate Gland: Acute suppurative prostatitis characterized by multiple abscesses in the interstitial tissue and intensive neutrophilic cell aggregation in the lumen of the prostatic acini, Fig. 14.

Control

Kidney: Occasional cortical tubules were lined with vacuolated epithelium in addition to atrophy of the glomeruli associated with dilated Bowman's capsule and accumulation of serous fluid in the lumen.

Testis: Degeneration of the germinal epithelial cells of some seminiferous tubules with formation of spermatid

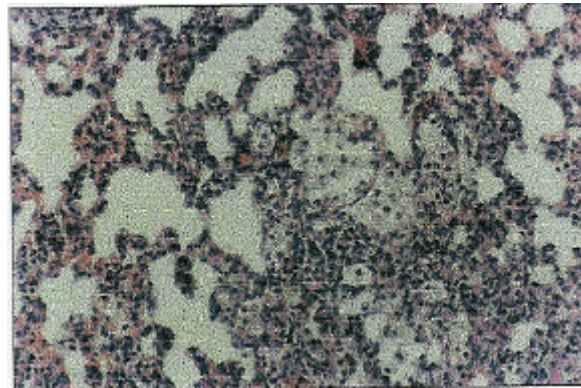


Fig. 3: Lung HXE X200
Foam cell aggregation in the alveolar lumen




Fig. 4: Lung HXE X100
Areas of chronic interstitial pneumonitis

giant cells were seen, Fig. 15.

Lung: Perivascular accumulation of round cell and areas of chronic interstitial pneumonitis were seen.

Discussion

Studies on the toxicity of *Anagallis arvensis* in rats gave LD₅₀ of 10.718 mg/kg.b.wt. IP. Acute toxic manifestation characterized by producing gastrointestinal symptom. Rats suffered from anorexia, restlessness, diarrhea, thirst (the animals goes towards drinking water), difficult breathing, tremors and ended by coma and death of some individuals by Watt and Breyer - Brandwijk (1962); Forsyth (1968); Kotb (1985).

Hematological results revealed severe anemia as remarked by decrease hemoglobin concentration, lowering of packed cell volume and marked fall in erthrocytic count. These results could be attributed to the harmful effect of saponin, an active principle of *Anagallis arvensis*, concerning to total WBCs count, there was no changes.

The elevated urea could be attributed to acute renal failure rather than to inadequate fluid intake, fluid diversion, or excessive external output (Oliver and

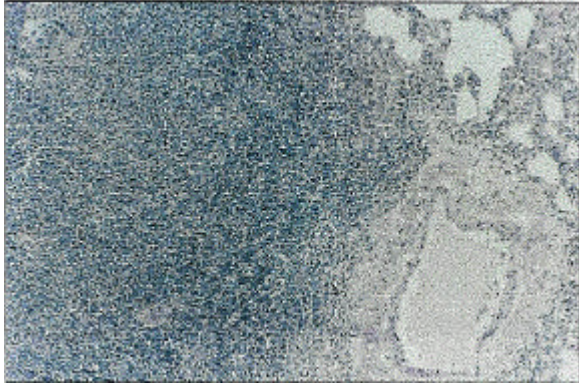


Fig. 5: Lung HXE
Lymphoid peri-bronchial hyperplasia X100

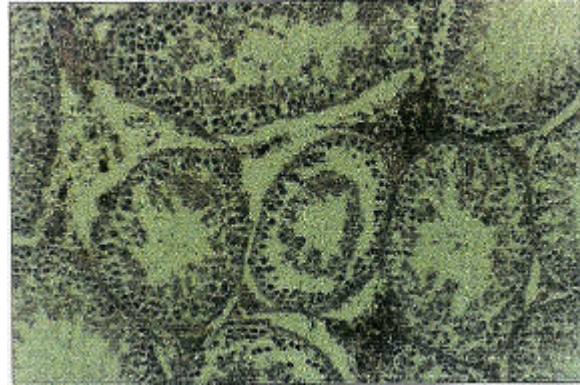

Fig. 8: Testis HXE
Degeneration of seminiferous tubules and interstitial Hemorrhage X200

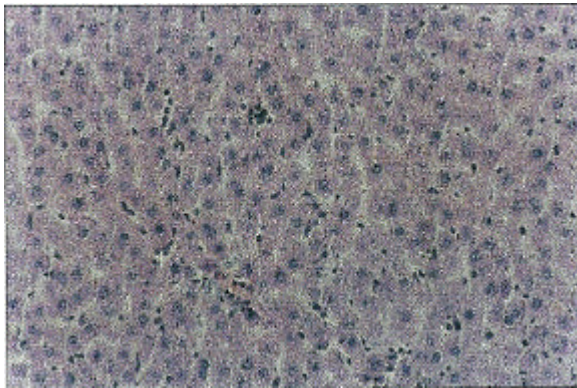


Fig. 6: Liver HXE
Kupffer hyperplasia X200

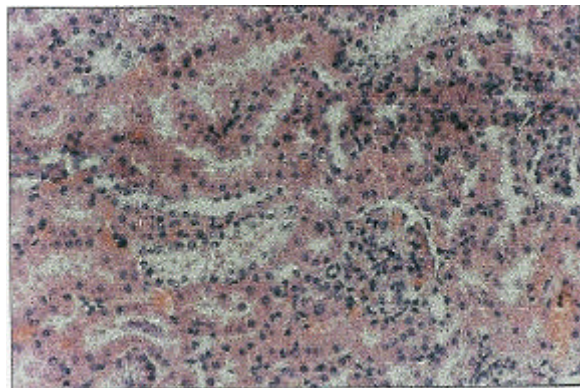


Fig. 9: Kidney HXE
The vacuolar degeneration of the P. C. T. X200




Fig. 7: Prostate gland HXE
Massive neutrophils cell infiltration in acini X200

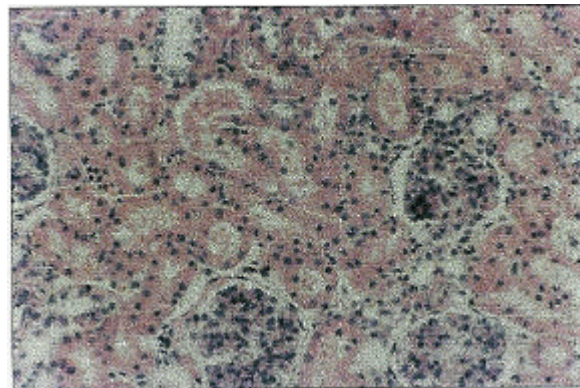


Fig. 10: Kidney HXE
The hyaline casts X200

Platonow, 1960) and tubular damage seen at the time of killing (Klein *et al.*, 1972; Tryphonas and Neilsen, 1973). The other opinion concerning normal level of urea are attributed to the plant, dose and period of treatment by the active principles.

The level of creatinine of the intoxication rats was increased significantly ($p < 0.05$). This increment is an indicator for renal function impairment due to toxicosis

by *Anagallis arvensis*. The results are impairment due to toxicosis by *Anagallis arvensis*. The results are in agreement with that obtained by Coles (1974), Metwalli (1987); El. Garieb (1990) who reported that a significant increase in creatinine level was indicative of kidney impairment and dysfunction. The significant increase in the level of creatinine may be regarded to glomerular

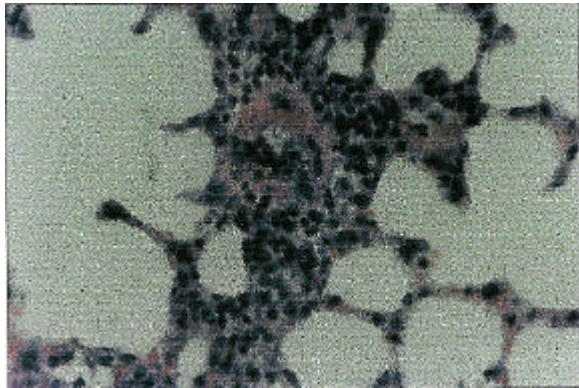


Fig. 11: Lung HXE X400
Endarteritis obliterans




Fig. 14: Prostate gland HXE X200
Interstitial edema and abscess formation

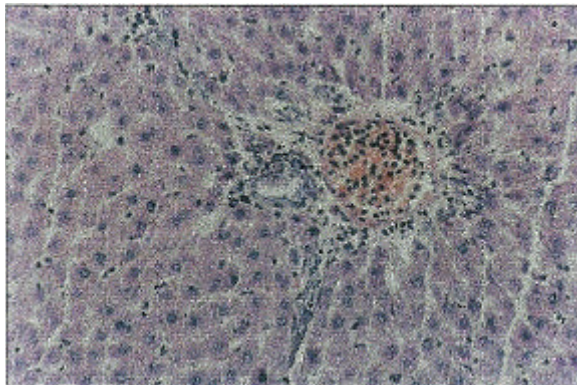


Fig. 12: Liver HXE X200
Congestion

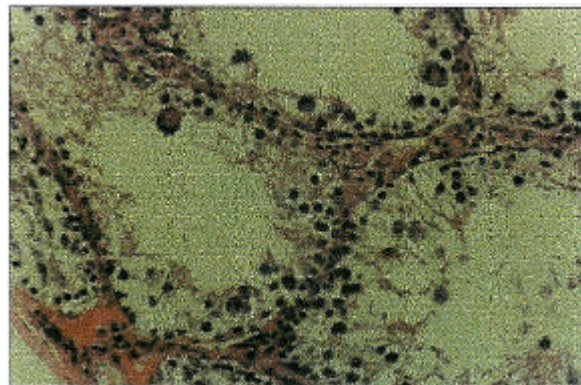


Fig. 15: Testes HXD X400
The testicular degeneration with spermatid giant cell formation

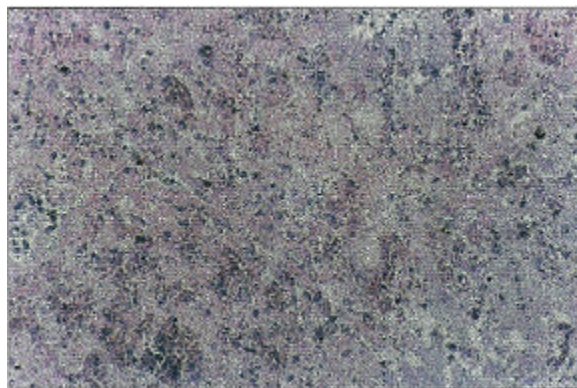


Fig. 13: Liver HXE X200
Congestion of hepatic sinusoids as parenchymal degeneration

damage and excessive muscular catabolism. Such a conclusion is confirmed by the present histopathological investigation which indicated glomerular damage (membranous glomerulonephritis) and corticotubular degeneration mainly the proximal convoluted tubule (nephrosis). These changes appeared dose related as by moderate and seen pathological change in the kidney

at low and high dose groups respectively. Such a conclusion is confirmed with those reported by Kelly (1984) who recorded that there was an increase in blood creatinine during severe renal damage, where the degree of rise can be more accurately correlated to the extent of glomerular damage in chronic nephritis than in acute renal impairment in which excessive muscular catabolism will artificially elevate the blood creatinine value.

The relation of the inflammatory changes observed in the prostate gland of one animal of groups 2 and 3 are of low significance as there is no indication of an edematous toxic effect on the genital organ that has been detected.

The changes observed in the liver and kidneys of treatment groups are more or less similar to those of the control animal and have no pathological significance.

It could be concluded that *Anagallis arvensis* was highly toxic to rats and induces several changes in the animal's tissues. It is potentially nephrotoxic.

References

Chevallier, A., 1996. The Encyclopedia of Medical Plants. A. Dorling Kindersley Book, London.

Al-Sultan et al.: Toxicity of *Anagallis Arvensis* Plant

- Coles, E., 1974. Veterinary Clinical Pathology. 2nd Ed. Philadelphia, London.
- Culling, C. P., 1974. Handbook of Histopathological Techniques. 2nd Ed. Butterworth Co. Ltd., London.
- El-Garieb, S., 1990. Metabolic disorder among sheep reared in Behera Governorate. M. V. Sc.Thesis, Fac. Vet. Med. Alexandria University.
- Fawcett, J. and J. Scott, 1960. A rapid and precise method for the determination of urea. J. Clin. Path., 13: 156.
- Forsyth, A. A., 1968. British poisonous plants. HMSO, London U. K. Ministry of Agriculture, Fisheries and food Bulletin 161, 84, 85 (amended, 1979, 85-86).
- Georgia, A., 1923. Manual of weeds. P.311 cited by Shihata (1954).
- Hurst, 1942. Cited in : Veterinary Toxicology Clarke, M.L.; Harvey, D. G. and Humphreys, D. J. (1981). 2nd Ed. Baillier Tindall, London, pp: 247.
- Kelly, W. R., 1984. Veterinary Clinical Diagnosis. 3rd Ed. Baillier Tindall, London.
- Klein, R., S. Herman, P. Brubaker, W. George, I. Lucier and M. Krigman, 1972. A model of acute methylmercury intoxication in rats. Arch. Pathol., 93: 408-418.
- Kotb, F. H., 1985. Medicinal plant in Libya. Arab Encyclopedia House, Beirut-Lebanon.
- Lander, G. D., 1944. Veterinary toxicology, 3rd Ed. Bailliere, Tindall & Cox. London, P: 245.
- Metwalli, A., 1987. Clinical Laboratory investigation on, a common disease manifestation among some farm animals. M. Vet. Med., Alexandria University.
- Miller, W. C., 1935. A veterinary dictionary, 2nd ED. Bailliere, Tindall and Cox. London, P: 769.
- Oliver, W. and N. Platonow, 1960. Studies on the Pharmacology of N. (ethylmercury) - P-toluensulfonamide. Am. J. Vet. Res., 21: 906-916.
- Pullar, E. M., 1939. Studies on five suspected poisonous plants. Aust. Vet. J., P: 15, 19-23.
- Riet-Correa, F., R. Rivero, F. Dutra, C. D. Timm and M. C. Mendez, 1998. Recently encountered poisonous plants of Rio Grande do Sul and Uruguay. In : Toxic plants and other natural toxicants, eds., Garland, T. and Barr, A. C., CAB International, New York, USA.
- Sadekar R. D., A. G. Bhandarker, S. C. Udasi, P. N. Deshmukh and B. S. Phadnaik, 1996. Toxicity of winter crop weed *Anagallis arvensis* (blue pimpernel) in cattle and buffaloes. Ind. Vet. J., 72: 1153.
- Schalm, O., 1975. Veterinary hematology, 2nd Ed. Bailline, Tindall and Cassel Ltd., London.
- Schneider, D. J., 1978. Fatal ovine nephrosis caused by *Anagallis arvensis*. J. Sou. Afr. Vet. Assoc., 49: 321-324.
- Seeling, H. and S. Wust 1969. Arztl. Lab., 15:34 [Cited in pamphlete of biochical Kits].
- Tryphnas, L. and N. Neilsen, 1973. Pathology of chronic alkylmercury poisoning in swine. Am. J. Vet. Res., 34: 379-392.
- Wahby, A. M., 1942. Egyptian plants poisonous to animal, 1st Ed. El-Horia Press, Cairo, P:16.
- Watt, J. M. and M. G. Breyer-Brandwijk, 1962. Medicinal and poisonous plants of Southern and Eastern Africa. E and S. Livingstone Ltd., Edinburgh and London, UK. P: 870.
- Weil, C., 1952. Tables for convenient calculation of median effective dose (LD₅₀ or ED50) and instructions in their use. Biometrics, 8: 249.
- Wintrobe, M., 1967. Clinical hematology. 6th Ed. Lea and Febiger, Philadelphia, U. S. A.