

Evidence for the Innervation of Sperm-host Glands (SHG) of Native Chicken's (*Gallus domesticus*) Oviduct

S. K. Das

Department of Anatomy and Histology, Faculty of Veterinary Science,
Bangladesh Agricultural University, Mymensingh-2202, Bangladesh
Email: shonkor@royalten.net

Abstract: The presence of neural tissues and smooth muscle elements in the vicinity of the oviductal sperm-host glands at uterovaginal junction of deshi chicken was demonstrated by medium (X40) and high (100X) light microscopy. Relevant samples were collected and passed through H and E stain in histology laboratory of the Department of Anatomy and Histology, BAU, Mymensingh, Bangladesh. Smaller and segregated nerve ganglions were observed in the submucosa and also in the lamina propria of the core of the villi by bright field microscopy. Smooth muscle fibers were also obvious in the surrounding areas. The evidence for the innervation of the sperm-host glands in chicken's oviduct suggested that it might have a functional role in oviductal sperm storage in and release of spermatozoa from, the sperm-host glands of native hens.

Key words: Innervation, sperm-host gland, oviduct and native chicken

Introduction

Innervation of any autonomous organ is considered as an important factor in controlling its function as normal physiology. As there is a possibility of the vascular system being in some way related to the control of the function of the sperm-host glands in hen's oviduct (Gilbert *et al.*, 1968), nervous system control in these glands might be considered as a functional determiner for spermatozoal storage and release. Though previous researchers were failed to identify the nerve supply to these glands (Gilbert, 1961; 1965a; 1965b; Gilbert *et al.*, 1968), recently it was well demonstrated by Freedman *et al.*, 2001 stating a clear evidence for innervation of these glands in the oviduct of turkey (*Meleagris gallopavo*), but no such other reports are available till now in native chicken. Thus the present study will simply demonstrate the presence of nervous tissue in the vicinity of these glands of native chicken's oviduct with a view to find out a reasonable relationship with the function of sperm-host glands with its innervation.

Materials and Methods

The birds used were single comb native chickens (*Gallus domesticus*), bought from the local market of Bangladesh Agricultural University campus having apparently good health and devoid of any external anatomical deformities. Then the birds were killed by cervical subluxation method. Immediately after killing, the abdominal and pelvic cavities were opened sufficiently to find out the oviduct. The oviducts of the birds were collected as soon as possible with the help of scalpel and scissors avoiding any destruction of the organ. Then the oviducts were placed on the tray straightly and samples were collected from infundibulum, uterovaginal junction and vagina with the

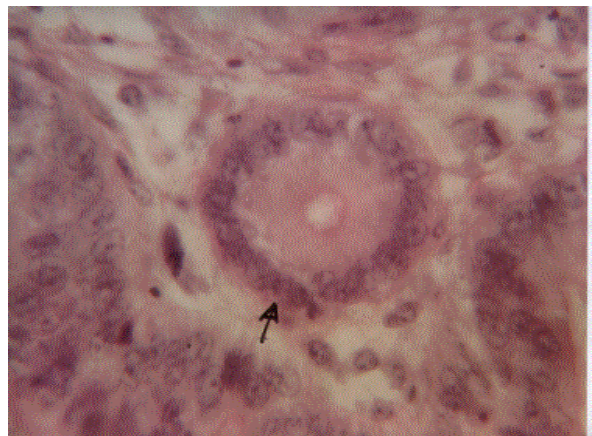


Plate 1: A typical SHG (arrow) at utero-vaginal junction (UVJ) of deshi hen's oviduct. X100.

help of sharp scalpel. For detail histological study, the tissues were of different segments of the oviduct (infundibulum, uterovaginal junction and vagina) were collected and fixed in the Buin's fluid for fixation. The tissues were then dehydrated in graded alcohol, cleared in xylene, embedded in paraffin and finally the sections were cut at 6 micron thickness using rotary microtome (Model 820, USA). The sections were then stained with standard Hematoxylin and Eosin (H & E) stain. Detail histological study was completed using medium (X40) high power light microscopy (X100). Photographs were placed for better illustration of the result.

Results and Discussion

Nerve supply to the sperm-host glands (Plate 1) of deshi chicken's oviduct was well defined in the present study

S. K. Das: Evidence for the Innervation of Sperm-host Glands of Native Chicken's (*Gallus Domesticus*) Oviduct

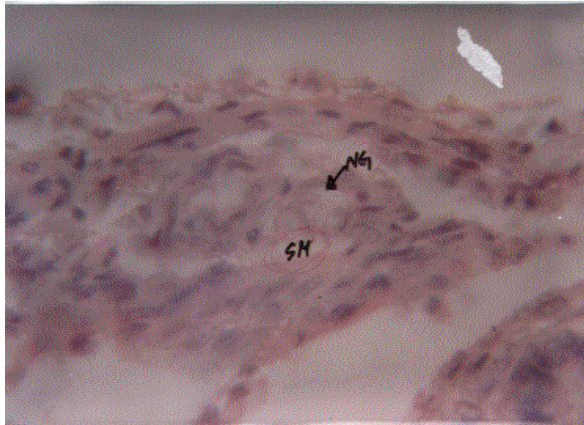


Plate 2: The infundibulum of deshi hen's oviduct showing nerve ganglion (NG) in the submucosa (SM). X100

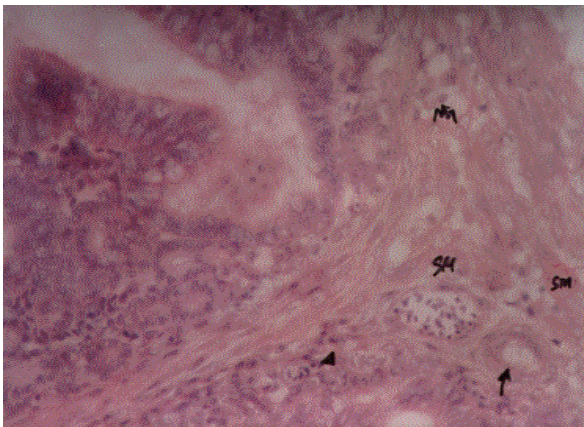


Plate 3: The infundibulum of deshi hen's oviduct showing nerve ganglion (NG) in the lamina propria and smooth muscles (sm) in the submucosa (SM) with arterial capillaries (arrow) and venous capillaries (arrowhead) surrounding the sperm-host glands (SHG). X40

showing smaller and segregated nerve ganglions in the submucosa (Plate 2) and in the lamina propria (Plate 3) of the core of the villi. The observation of this present study have close similarity with the observation of Freedman *et al.*, 2001. They stated that there present neural tissue and smooth muscle element in the vicinity of the oviductal sperm storage tubules at uterovaginal

junction. Isolated neurons and small ganglia were also identified in the tunica mucosa by bright field microscopy.

Many researches were conducted regarding the histology of the chicken's oviduct along with sperm-host glands but they somehow overlooked the innervation matter. Few researchers were also failed to identify the neural tissue in this organ related to sperm-host glands (Gilbert, 1961; 1965a; 1965b; Gilbert *et al.*, 1968). They stated that these glands are not innervated. Failure to discover any nervous tissue associated with the host glands was probably the fault of the method used, or staining procedure, although specific stains for nervous tissue was used by Gilbert *et al.*, 1968.

In reality, innervation of the sperm-host glands is a physiological matter and it always present in this organ. Thus in conclusion, it can be stated that nervous tissue present in the deshi chicken's oviduct related to sperm-host glands, might have a functional role in oviductal sperm storage in and release of spermatozoa from, but it need a further investigation to clarify how it occurs.

Acknowledgements

The author is grateful to the Department of Anatomy and Histology, BAU, Mymensingh-2002, Bangladesh for providing facilities for histological works. Sincere thanks also go to MD. Ashraful Haque, Md. Nurul Islam and Md. Sultan for their continuous cooperation during the experimental tenure.

References

- Freedman, S. L., V. G. Akuffo and M. R. Bakst, 2001. Evidence for the innervation of the sperm storage tubules in the oviduct of turkey (*Meleagris Gallopavo*). *Reproduction Cambridge*, 121: 5, 809-814: 22 ref.
- Gilbert, A. B., 1961. The innervation of the renal portal valve of the domestic fowl. *J. Anat.*, 95: 594.
- Gilbert, A. B., 1965a. Innervation of the ovarian follicle of the domestic hen. *Q. Jl exp. Physiol.*, 50: 437.
- Gilbert, A. B., 1965b. Triple silver impregnation for selective staining of avian nerves. *Stain Tech.*, 40: 301.
- Gilbert, A. B., M. E. Reynolds and F. W. Lorenz, 1968. Distribution of spermatozoa in the oviduct and fertility of domestic birds. VII. The innervation and vascular supply of the utero-vaginal sperm-host glands of the domestic hen. *J. Reprod. Fert.*, 17: 305.